

Con el aval científico de:



Sociedad Española de Anatomía Patológica

Madrid, 9 de mayo de 2012

# USCAP & AACR HIGHLIGHTS

Patología del hueso y partes blandas

*Dr. Ricardo González Cámpora – Hosp. Univ. Virgen Macarena, Sevilla*

USCAP  
& AACR  
HIGHLIGHTS  
2012

## [19] Frequent PLAG1 Gene Rearrangements in Skin and Soft Tissue Myoepithelioma (ME) with Ductal Differentiation

*Cristina R Antonescu, Lei Zhang, Sung Yun Shao, Christopher D Fletcher. Memorial Sloan Kettering Cancer Center, New York, NY; Brigham & Women's Hospital, Boston, MA.*

- ▶ **Background:** A subset of cutaneous and superficial ME tumors display a distinct ductal component and closely resemble mixed tumors/pleomorphic adenomas of salivary gland. As *PLAG1* and *HMGA2* gene rearrangements are the most common genetic events in pleomorphic adenomas, we sought to investigate if these abnormalities are also present in the skin/soft tissue ME lesions. In contrast, half of the deep-seated soft tissue ME tumors lacking ductal differentiation are known to be genetically unrelated, showing *EWSR1* gene rearrangements.
- ▶ **Design:** FISH analysis to detect *PLAG1* and *HMGA2* gene abnormalities was performed in 33 ME tumors, 8 from skin and 25 from soft tissue, lacking *EWSR1* gene rearrangements. For the *PLAG1* rearranged tumors, FISH and RACE was performed to identify potential fusion partners, including *CTNNB1* (*beta-catenin*) on 3p21 and *LIFR* (*leukemia inhibitory factor receptor*) on 5p13.
- ▶ **Results:** Recurrent *PLAG1* gene rearrangement by FISH was detected in 11 (33%) lesions, including 2 (25%) in the skin and 9 (36%) in the soft tissue. All were classified as benign morphologically and all except one showed abundant tubulo-ductal differentiation (comprising 10/22 [45%] of all tumors with ductal structures). A *PLAG1-LIFR* fusion was detected by RACE and then confirmed by FISH in one soft tissue ME tumor with tubular formation. No *CTNNB1* or *LIFR* abnormalities were detected in any of the remaining *PLAG1*-rearranged tumors. No *HMGA2* gene abnormalities were detected in any of the 22 ME lesions tested.
- ▶ **Conclusions:** A subset of cutaneous and soft tissue ME tumors appear genetically linked to their salivary gland counterparts, displaying frequent *PLAG1* gene rearrangements and occasionally *PLAG1-LIFR* fusion.  
Category: Bone & Soft Tissue

## [29] Recurrent t(4;19) Translocation with CIC-DUX4 Fusion in a Novel Highly Malignant Small Round Cell Soft Tissue Sarcoma

*Eun-Young K Choi, Dafydd G Thomas, Jonathan B McHugh, Rajiv M Patel, Diane Roulston, Christopher Wienczewski, Mitul B Amin, David R Lucas. University of Michigan, Ann Arbor, MI; William Beaumont Hospital, Royal Oak, MI.*

- ▶ **Background:** Translocation-associated sarcomas are defined by distinctive histologic patterns and clinical behavior. Only 8 cases of small round cell soft tissue sarcomas (SRCSTS) harboring t(4;19)(q35;q13.1) have previously been reported, mostly in the pediatric population. In these tumors, *CIC* on chr 19 fuses with *DUX4* on chr 4 resulting in a putative oncogene, *CIC-DUX4*. Herein we describe 4 new cases of SRCSTS harboring this novel recurrent translocation in young adult patients.
- ▶ **Design:** We identified 2 initial cases of SRCSTS with complex karyotypes that had t(4;19)(q35;q13.1) translocations. To confirm *CIC-DUX4* fusion and to identify additional cases with t(4;19), we designed RT-PCR primers to detect *CIC-DUX4* fusion and FISH probes to detect *CIC-DUX4* fusion as well as chr 19q13 break-apart. Paraffin blocks from 19 additional cases with similar histologic findings to our initial 2 cases were selected for *CIC-DUX4* testing.
- ▶ **Results:** RT-PCR and FISH assays for *CIC-DUX4* fusion and chr 19q13 break-apart confirmed *CIC-DUX4* fusion in our initial 2 cases, which were also negative for Ewings and synovial sarcoma translocations by cytogenetics, RT-PCR and FISH. Of the 19 additional cases, 2 were positive for the *CIC-DUX4* fusion by FISH and negative for *EWS-FLI1* by RT-PCR. The cohort consisted of 2 women (ages 25 & 32) and 2 men (ages 20 & 31). Each presented with a rapidly growing soft tissue mass (mean tumor size 12.8 cm). 2 were located in the thigh, and 1 each in the perineum and calf. All 4 tumors had similar histological features consisting of sheets of primitive small round blue cells with scant cytoplasm, slightly myxoid background, and large zones of necrosis. Only 1 tumor expressed CD99. All 4 patients received neoadjuvant and adjuvant chemotherapy and surgical resection of the primary tumor. 2 had lung metastasis at presentation and a third developed lung and spine metastases 6 months after presentation; all 3 were unresponsive to therapy and died of disease (mean survival 10.6 months). The fourth patient responded to therapy and is alive without evidence of recurrence or metastasis at 27 months.
- ▶ **Conclusions:** *CIC-DUX4* primitive SRCSTS represents a novel translocation-associated sarcoma. Our preliminary results suggest aggressive clinical behavior and failure to respond to conventional treatment. Additional FISH and RT-PCR assays are currently being performed for further confirmation and to identify more cases. The results will be reported at the meeting.  
Category: Bone & Soft Tissue

## [70] Rearrangement of *DDIT3* (*CHOP*) in Perivascular Epithelioid Tumors (PEComas): A Novel Finding

*Karen E Schoedel, Carol Sherer, Kathleen Cieply, Andrew L Folpe. University of Pittsburgh Medical Center, Pittsburgh, PA; Mayo Clinic, Rochester, MN*

- ▶ **Background:** The genetic events underlying the development of soft tissue perivascular epithelioid tumors (PEComas) have not been fully elucidated. A prior comparative genomic hybridization study has shown genetic gains and losses on several chromosomes including gains involving X, 12q, 3q, 5 and 2q. Loss of expression of the tumor suppressor genes *TSC1* and *TSC2* has also been shown in some PEComas. Prompted by a recent case of PEComa found during routine pathological evaluation to have rearrangement of *DDIT3*, we evaluated a larger series of well-characterized PEComas of soft tissue, gynecologic and cutaneous origin for evidence of *DDIT3* rearrangement.
- ▶ **Design:** Inclusive of the index case, 13 morphologically and immunophenotypically classical PEComas were retrieved from our institutional and consultation archives. In each case, H&E stained slides were reviewed and tumor areas marked. Three corresponding unstained slides were submitted for FISH analysis using the Vysis LSI *DDIT3* dual color break apart probe. Approximately 60 cells were evaluated in each case and the cutoff value for positivity was 15.5%.
- ▶ **Results:** The tumors occurred in 4 male and 9 female patients, ranging in age from 28 to 72 years (mean 49 years). Tumors involved soft tissue/viscera (N=7), skin (N=4), and uterus (N=2). Cases were classified as histologically benign (N=8), of uncertain malignant potential (N=1) and histologically malignant (N=4). Rearrangements of the *DDIT3* locus were identified in 3/13 cases (23%), all of soft tissue origin (1 malignant, 1 uncertain, 1 benign).
- ▶ **Conclusions:** This represents, to the best of our knowledge, the first report of *DDIT3* rearrangements in PEComas. This finding suggests the presence of a *DDIT3*-containing translocation in at least a subset of PEComas, although the fusion partner(s) is (are) currently unknown. It is unlikely that *DDIT3* rearrangement will prove to be related to clinical behavior in PEComas, given its presence in tumors both with and without morphological features of malignancy. *DDIT3* is known to be involved in adipocyte differentiation, cell cycle progression and malignant transformation, and may prove to be important in the pathogenesis of PEComas.

Category: Bone & Soft Tissue

## [27] Loss of Retinoblastoma Protein Expression in Spindle Cell/Pleomorphic Lipomas and Cytogenetically Related Tumors: An Immunohistochemical Study with Diagnostic Implications

*Benjamin J Chen, Leona A Doyle, Christopher DM Fletcher, Jason L Hornick. Brigham and Women's Hospital & Harvard Medical School, Boston, MA*

- ▶ **Background:** Spindle cell lipoma is a circumscribed subcutaneous tumor that typically arises on the upper back or neck of older male patients. Spindle cell lipoma is composed of an admixture of adipocytes, short spindle cells, and ropey collagen bundles in variable proportions, sometimes with a myxoid stroma; pleomorphic lipoma is a variant containing floret-like giant cells. Consistent rearrangements of chromosomes 13q and 16q have been identified by cytogenetics. Mammary-type myofibroblastoma and cellular angiofibroma show overlapping histologic features and similar chromosomal losses, suggesting a possible relationship among these tumor types. The tumor suppressor gene *RB1*, encoding the retinoblastoma (Rb) protein, is located at 13q14, within a minimally deleted region in spindle cell lipoma. The purpose of this study was to examine expression of Rb by immunohistochemistry (IHC) in spindle cell lipoma, pleomorphic lipoma, mammary-type myofibroblastoma, and cellular angiofibroma, as well as histologic mimics, to determine its potential diagnostic utility.
- ▶ **Design:** Whole tissue sections of 194 tumors were evaluated: 18 spindle cell lipomas, 20 pleomorphic lipomas, 19 mammary-type myofibroblastomas, 16 cellular angiofibromas, 22 conventional lipomas (8 intramuscular), 18 atypical lipomatous tumors (all positive for MDM2 and CDK4), 19 solitary fibrous tumors, 19 myxoid liposarcomas, 14 hibernomas, 11 deep (aggressive) angiomyxomas, 9 angiofibromas, and 9 vulval fibroepithelial stromal polyps. IHC was performed following pressure cooker antigen retrieval using a mouse anti-Rb monoclonal antibody (1:100; G3-245; BD Biosciences). Nuclear staining for Rb was scored as "intact" or "deficient".
- ▶ **Results:** Rb expression was deficient in all spindle cell lipomas, pleomorphic lipomas, and cellular angiofibromas and in 17 (89%) mammary-type myofibroblastomas. Rb staining was sometimes difficult to interpret in cellular angiofibromas with reactive stromal changes. Rb was also deficient in 2 (9%) conventional lipomas. Rb expression was intact in all other tumor types evaluated.
- ▶ **Conclusions:** Of the soft tissue tumors associated with 13q deletions, all spindle cell lipomas, pleomorphic lipomas, and cellular angiofibromas and most mammary-type myofibroblastomas show loss of Rb expression. Rb expression is intact in histologic mimics. These findings reinforce the pathogenetic relationship among this group of tumors and demonstrate the potential diagnostic utility of IHC for Rb.

Category: Bone & Soft Tissue

## [41] Solitary Fibrous Tumor: Is There a Molecular Relationship with Cellular Angiofibroma, Spindle Cell Lipoma and Mammary-Type Myofibroblastoma?

*Karen J Fritchie, Yang Sun, Galina Batiouchko, Paula Carver, Steven D Billings, Brian P Rubin, Raymond R Tubbs, John R Goldblum. Mayo Clinic, Rochester, MN; Cleveland Clinic, Cleveland, OH.*

- ▶ **Background:** Solitary fibrous tumor (SFT) is a distinct mesenchymal tumor characterized by ovoid to spindled cells, characteristic thick-walled branching (“staghorn”) blood vessels, stromal hyalinization, variable amounts of lipomatous differentiation and immunoreactivity for CD34. Recent studies have shown loss of 13q in a group of morphologically similar entities including cellular angiofibroma, mammary-type myofibroblastoma and spindle cell lipoma. The histologic and immunophenotypic overlap between solitary fibrous tumor and the latter group of tumors has been recognized, raising the possibility that all four of these tumors may be genetically linked.
- ▶ **Design:** We tested a group of 40 SFTs including some malignant SFTs to assess for loss of *RB1* (13q14) by fluorescence in situ hybridization (FISH). Additionally, a group of cellular angiofibromas (1 case), spindle cell lipomas (6 cases) and mammary-type myofibroblastomas (4 cases) were analyzed as a control group.
- ▶ **Results:** All cases (38/38) of solitary fibrous tumor with evaluable signals failed to show loss of *RB1* (13q14) by FISH while all cases of cellular angiofibroma (1/1), spindle cell lipoma (6/6) and mammary-type myofibroblastoma (4/4) showed either monoallelic or biallelic loss of *RB1*.
- ▶ **Conclusions:** Although solitary fibrous tumor may share overlapping morphologic and immunophenotypic features with cellular angiofibroma, mammary-type myofibroblastoma and spindle cell lipoma, the absence of *RB1* loss suggests that they are not related genetically.

Category: Bone & Soft Tissue

## [36] MUC4 Is a Sensitive and Specific Marker for Sclerosing Epithelioid Fibrosarcoma: Association with *FUS* Gene Rearrangement

*Leona A Doyle, Wei-Lien Wang, Paola Dal Cin, Alexander J Lazar, Christopher DM Fletcher, Jason L Hornick. Brigham and Women's Hospital & Harvard Medical School, Boston, MA; The University of Texas M.D. Anderson Cancer Center, Houston, TX.*

- ▶ **Background:** Sclerosing epithelioid fibrosarcoma (SEF) is a rare aggressive fibroblastic neoplasm composed of cords of epithelioid cells embedded in a dense collagenous stroma. The reported immunophenotype of SEF is non-specific. Some SEF cases show morphologic and molecular overlap with low-grade fibromyxoid sarcoma (LGFMS), suggesting a relationship between these tumor types. MUC4 has recently been identified as a sensitive and specific marker for LGFMS; MUC4 expression was also observed in 2 tumors with hybrid features of SEF and LGFMS. We investigated MUC4 expression in SEF and other epithelioid soft tissue tumors to determine (1) the potential diagnostic utility of MUC4 for SEF and (2) the association between MUC4 expression and *FUS* rearrangement in SEF.
- ▶ **Design:** Whole sections of 146 tumors were evaluated: 34 SEF cases (8 hybrid LGFMS/SEF), 20 epithelioid sarcoma, 11 clear cell sarcoma, 11 metastatic melanoma, 10 PEComa, 10 alveolar soft part sarcoma, 10 epithelioid angiosarcoma, 10 epithelioid hemangioendothelioma, 10 epithelioid gastrointestinal stromal tumor (GIST), 10 myoepithelial carcinoma (MEC), and 10 biphasic synovial sarcoma (B-SYS). Immunohistochemistry was performed following antigen retrieval using a mouse anti-MUC4 monoclonal antibody (1:500; 8G7; Santa Cruz). FISH was performed on 33 SEF cases using *FUS* break-apart probes (Abbott).
- ▶ **Results:** Strong diffuse cytoplasmic staining for MUC4 was observed in 25 of 34 (74%) SEF cases, including all 8 hybrid tumors. *FUS* rearrangement was found in 7 of 20 (35%) MUC4-positive SEF cases with successful FISH. The prevalence of *FUS* rearrangement was similar in hybrid LGFMS/SEF and SEF cases without an LGFMS component. *FUS* rearrangement was not detected in any MUC4-negative SEF cases. MUC4 expression was also seen in 9 of 10 (90%) B-SYS cases, predominantly in the glandular component. All other tumor types were negative for MUC4, apart from focal reactivity in 2 epithelioid GISTs and 1 MEC.
- ▶ **Conclusions:** MUC4 is a sensitive and relatively specific marker for SEF. MUC4 expression correlates with glandular epithelial differentiation in B-SYS and is very limited in other epithelioid soft tissue tumors. These findings suggest that SEF are biologically heterogeneous. MUC4-positive SEF with *FUS* rearrangement are likely closely related to LGFMS. MUC4-positive SEF that lack *FUS* rearrangement may be related to LGFMS but could have alternate gene fusions. SEF without MUC4 expression probably represent a distinct group of tumors.

Category: Bone & Soft Tissue

## [66] Muc-4 Expression and FUS Rearrangement in Sclerosing Epithelioid Fibrosarcomas: A Pathological Study of 20 Cases Further Supporting Relationship with Low Grade Fibromyxoid Sarcoma

*Florian Puls, Khin Thway, Angela Niblett, Florian Laenger, Vaiyapuri Sumathi, Cyril Fisher, Chas C Mangham, Lars-Gunnar Kindblom. Royal Orthopaedic Hospital, Birmingham, United Kingdom; Royal Marsden Hospital, London, United Kingdom; Medical School Hannover, Hannover, Germany; Robert Jones & Agnes Hunt Orthopaedic Hospital, Oswestry, United Kingdom.*

- ▶ **Background:** Sclerosing epithelioid fibrosarcoma (SEF) is an aggressive sarcoma with a predilection for the deep soft tissues of the extremities and trunk and a propensity for local recurrence, metastasis and tumor-related death. A subset of SEF shows morphologic and molecular overlap with low grade fibromyxoid sarcomas (LGFMS). LGFMS characteristically harbors FUS-CREB3L1/L2 and has recently been shown to express Muc-4, which can be used as a diagnostic immunohistochemical marker. We have studied MUC-4 expression and evidence of FUS rearrangement in a large series of SEF. Pathological findings and clinical outcome were compared to a cohort of 14 "classic" LGFMS.
- ▶ **Design:** 20 cases of SEF and 14 LGFMS were retrieved, reviewed and stained for Muc-4. RT-PCR and/or FISH for FUS-break apart were performed. Clinical follow up was obtained.
- ▶ **Results:** 14/20 SEF and 14/14 LGFMS showed Muc-4 expression; FUS-rearrangement was detected in 2/9 SEF (both Muc-4 positive) and 8/8 LGFMS tested. Clinical follow up was obtained from 19 SEF cases (4 to 216, median 31 months) and 13 LGFMS (2 to 121, median 37 months). Metastatic disease occurred in 14/19 SEF patients (metastasis-free survival 0 to 120, median 12 months) and 6 patients died of tumor (survival 4 to 73, median 31.5 months). There was no significant difference between Muc-4 positive and Muc-4 negative SEF with regard to metastasis and overall survival. Of 13 LGFMS cases, 3 had metastasized (2 at presentation, one after 53 months), all alive 2, 7 and 121 months after diagnosis. Metastasis-free survival and overall survival of Muc-4 positive SEF were significantly shorter when compared to LGFMS.
- ▶ **Conclusions:** A high proportion of SEF expresses Muc-4 and a smaller proportion shows FUS rearrangement. The findings support a histogenic relationship between LGFMS and SEF. The fact that SEF shows a more aggressive biological behavior in respect to metastatic potential and survival justifies the continuous distinction between the entities.

Category: Bone & Soft Tissue

## [75] Assessment of MUC4 Expression in Primary Bone Sarcomas

*Roberto Tirabosco, Fitim Berisha, Dina Halai, Hongtao Ye, Anupama Swamy, Maria Fernanda Amary, Adrienne Flanagan. Royal National Orthopaedic Hospital, Stanmore - London, United Kingdom.*

- ▶ **Background:** Mucin 4 (MUC4), a glycoprotein expressed in various types of carcinomas, has been recently highlighted as a specific and sensitive immunohistochemical marker of low grade fibromyxoid sarcoma (LFS), a soft tissue tumor the hallmark of which is the t(7;16)(q33;p11). Since it is recognised that osteosarcoma - the most frequent primary bone sarcoma - can mimic virtually all other tumors thereby making them difficult to diagnose, particularly on needle cores, we sought to analyse the expression of MUC4 on a series of primary malignant bone tumors, as such data are not available in the literature. Review of our pathology archive revealed that we had previously reported 2 tumors with morphological features consistent with LFS and the closely related epithelioid sclerosing fibrosarcoma (ESF), a tumor which has been rarely reported as occurring in bone.
- ▶ **Design:** To address the sensitivity and specificity of MUC4 expression in sarcomas, in addition to primary bone tumors we included a series of soft tissues neoplasms, some of which may rarely arise in bone. Tissue microarrays, prepared at our Institution, including 120 osteosarcomas, 220 chondrosarcomas, 45 chordomas, 60 myxofibrosarcomas, 54 solitary fibrous tumors, 59 leiomyosarcomas and 90 synovial sarcomas were studied. Whole tissue sections of 8 ossifying fibromyxoid tumors and the 2 cases with features consistent with ESF (*FUS*-rearrangement negative) and LFS (*FUS*-rearrangement not informative) were analyzed. For comparison, 8 cases of ESF of soft tissue (*FUS*-rearrangement negative) were added. Ten *FUS*-rearrangement positive LFS were used as control. Immunohistochemistry was performed using standard methods.
- ▶ **Results:** All LFS with the characteristic t(7;16) expressed MUC4 diffusely. The 2 primary ESF/LFS of bone were diffusely positive for MUC4. Three out of 8 ESF of soft tissue (37.5%) were diffusely immunoreactive for MUC4 and 22/90 SS (24.4%) were focally positive. All the remaining tumors were negative for MUC4.
- ▶ **Conclusions:** We have identified 2 cases of *bona fide* primary malignant bone tumors that displayed morphological features consistent with LFS (scapula) and ESF (femur), which diffusely express MUC4. 25% of SS expressed MUC4 focally, mostly byphasic type, thereby confirming previously published data. We conclude that once a diagnosis of SS is excluded, it is very unlikely that tumors in bone other than LFS and ESF, express MUC4. We recommend that MUC4 expression is studied in all fibromyxoid and sclerosing tumors of bone, in order to improve the classification of primary bone tumors, as this may help stratify patients for neo-adjuvant treatment.

Category: Bone & Soft Tissue

## [20] Angiomatoid Fibrous Histiocytoma: An Expansion of the Histologic Spectrum

*Summer L Bohman, Brian P Rubin, John R Goldblum, Munir R Tanas, Steven D Billings. Cleveland Clinic Foundation, Cleveland.*

- ▶ **Background:** Angiomatoid fibrous histiocytoma (AFH) is a tumor of intermediate malignancy that usually presents on extremities of children/young adults. Classically, AFH is composed of histiocyte-like cells with round to oval nuclei with pseudovascular spaces, hemorrhage and hemosiderin and is surrounded by a fibrous pseudocapsule with a peripheral lymphocytic cuff. AFH frequently have translocations involving *EWSR1*, or less commonly *FUS*. Morphologic variants have been described, but some cases of AFH cause diagnostic difficulty and this tumor is a frequent source of consultation. We reviewed our experience with AFH and emphasize unusual histologic features.
- ▶ **Design:** Detailed histologic examination was performed, evaluating classic features, unusual features and mitotic rates. In cases with blank slides/blocks, immunostains for CD68, desmin and EMA and FISH for the *EWSR1* translocation were performed. Demographics were also reviewed.
- ▶ **Results:** 26 cases met selection criteria. A broad morphologic spectrum was observed. In addition to classic histologic features, 9 cases displayed various degrees of sclerosis with 3 displaying a focal swirling perineurioma-like pattern, with 1 having a diffuse perineurioma-like pattern. Nine cases had at least moderate pleomorphism, with 2 having striking pleomorphism. 8 had eosinophils, one with numerous eosinophils throughout the tumor. Atypical mitotic figures were seen in 3, including two pleomorphic AFHs and the case with numerous eosinophils. One had reticular/myxoid morphology. Evidence of a *EWSR1* translocation was seen in 11/15 tested. One pleomorphic AFH was aneusomic for *EWSR1*, suggesting a cryptic translocation. Immunohistochemically, 69% expressed EMA, 53% desmin and 63% CD68. With the exception of one case, all had  $\geq 2$  of the classic findings: peripheral lymphocytic cuff, fibrous pseudocapsule, pseudovascular spaces, hemorrhage and hemosiderin. The single exception only had a lymphocytic cuff. In review of the demographics data, 5 (19%) occurred in patients  $>40$  years old, and 9 (35%) were located outside the extremities. Three (12%) occurred in patients  $>40$  years old and in atypical locations.
- ▶ **Conclusions:** AFH has a broader histologic and clinical spectrum than is commonly recognized. In addition to conventional features, sclerosis, perineurioma-like areas, marked eosinophilia, atypical mitotic figures, marked pleomorphism, and complex cytogenetic aberrations involving *EWSR1* may be seen. Many typical histologic features may be absent. Knowledge of this morphologic spectrum with utilization of FISH is helpful in AFH with unusual features.

Category: Bone & Soft Tissue

## [58] Angiofibroma of Soft Tissue: Clinicopathologic Characterization of a Distinctive Benign Fibrovascular Neoplasm in a Series of 37 Cases

*Adrian Marino-Enriquez, Christopher DM Fletcher. Brigham and Women's Hospital and Harvard Medical School, Boston, MA.*

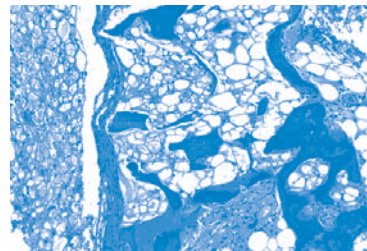
- ▶ **Background:** Fibroblastic tumors with prominent vascularization are rare, mainly limited to nasopharyngeal angiofibroma and cellular angiofibroma. We have become aware of a distinct benign soft tissue neoplasm with fibroblastic cytology and a very noticeable vascular pattern which may be mistaken for a low grade sarcoma.
- ▶ **Design:** Thirty-seven cases of a distinctive benign fibrovascular soft tissue tumor identified between 2000 and 2011 were retrieved from consultation files. Clinicopathologic and follow-up information was obtained from referring pathologists. H&Es were reviewed. IHC stains for CD34, EMA, SMA, desmin and S100 were performed.
- ▶ **Results:** Patients were 25 women and 12 males, aged 6-86 years old (median 49 y). The tumors presented most commonly as a slowly growing painless mass in the soft tissues of the extremities, mainly the lower extremity, often in relationship to joints or fibrotendinous structures. Most lesions (29) were well circumscribed, 1.2-12 cm in size (median 3.5 cm). Microscopically, they were characterized by 2 components: a uniform proliferation of bland, spindle-shaped cells with inconspicuous cytoplasm and ovoid nuclei set in a variably myxoid stroma, and a prominent vascular network with numerous small branching thin-walled blood vessels, often accompanied by medium-sized round or ectatic vessels. Mitoses (1-4/10 hpf) were occasionally present (9 cases). Mild degenerative nuclear atypia was uncommon (5 cases). Tumor cells expressed EMA (usually focally) in 16/36 cases (44%), CD34 and SMA in 5 (14%) and desmin in 4 (11%); none expressed S100 protein. Cytogenetically, 5 out of 6 cases analyzed showed simple karyotypes with a balanced t(5;8) translocation. All patients were treated by surgical excision. Follow-up information was available for 28 patients (range 6-144 months; mean 51.9 months). Most patients showed no evidence of disease, regardless of the status of surgical resection margins. Four patients developed local recurrence 9, 13, 36 and 120 months after the primary tumor was removed; one developed a second recurrence 2 months later. None of the patients developed metastasis.
- ▶ **Conclusions:** Angiofibroma of soft tissue is a previously unrecognized fibrovascular soft tissue tumor with distinctive morphology, arising most commonly in the extremities of middle aged adults. Preliminary data suggest that these tumors have a distinct and reproducible karyotype. The clinical course is benign, with rare local recurrences and no evident metastatic potential. Simple local excision seems to be adequate treatment.

Category: Bone & Soft Tissue

## [46] Chordoma Arising in Benign Notochordal Cell Tumor: A Detailed Radiological, Gross and Microscopic Description of Three Cases Involving the Lumbar Spine

*Shady Elia A Ishak, G Petur Nielsen, Andrew E Rosenberg. Cairo University, Cairo, Egypt; Massachusetts General Hospital, Boston, MA; University of Miami, Miami, FL*

- ▶ **Background:** Chordoma is a rare primary malignant bone neoplasm that recapitulates the embryonic notochord. It arises almost exclusively in the axial skeleton with predilection for its proximal and distal segments. The pathogenesis of chordoma is still unknown, however, some investigators have suggested that it develops from benign notochordal cell tumor (BNCT) based on demonstrating both lesions in the same patient or by illustrating that they have the same anatomical distribution.
- ▶ **Design:** We identified from the surgical pathology files of the department of pathology of Massachusetts General Hospital and the consultation files of one of the authors three cases of chordoma arising directly adjacent to BNCT. The radiological, gross and microscopic features were carefully analyzed.
- ▶ **Results:** The three tumors arose in two women and one man and their ages were 42, 17 and 31 respectively. On imaging studies the BNCT manifested as an irregular region of sclerosis located within the center of the vertebral body and the chordoma appeared as an oval area of lytic destruction that was centered posterior to the BNCT and transgressed the cortex and extended into the spinal canal.



Microscopically, both lesions demonstrated characteristic histologic features and were juxtaposed to one another.

- ▶ **Conclusions:** Hypotheses regarding the etiology of chordoma have largely been speculative with very few published examples of both lesions intimately related to one another. Our study clearly demonstrates the anatomic proximity of the two neoplasms provides further evidence that BNCT is the precursor lesion for chordoma.

Category: Bone & Soft Tissue

## [54] The Benign Notochordal Cell Tumor and Echordosis Physaliphora Lack the Complex Genomic and Genetic Alterations Commonly Found in the Conventional Chordomas

*Yang D Lee, Long P Le, Vikram Deshpande, Anthony J Iafrates, Andrew E Rosenberg, G Petur Nielsen. Massachusetts General Hospital, Boston, MA; University of Miami, Miami.*

- ▶ **Background:** Chordoma is a low-grade malignant neoplasm of the axial skeleton, with a histological appearance similar to the notochord present in early embryogenesis. Previous analyses of chordoma using cytogenetics, fluorescent in situ hybridization (FISH), and array comparative genomic hybridization (aCGH) have revealed heterogeneous and complex alterations including chromosomal-scale loss and gain, focal gene amplifications, translocations, and chromotripsis. Although some of these complex alterations can contribute to the malignant nature of chordoma, the majority of these genomic changes likely represent either late events of tumorigenesis or passenger mutations caused by genomic instability. The early origin of chordoma has remained enigmatic although there is evidence that they arise from a precursor lesion - benign notochordal cell tumor (BNCT). BNCTs share certain cytologic similarities to the conventional chordoma and may be distinguished from the latter morphologically, albeit at times this is very challenging. Another related notochordal lesion is echordosis physaliphora (EP). EPs are basilar-pontine lesions which also share histological similarities to the conventional chordoma. But unlike chordoma, they are often discovered incidentally during autopsy, and are thought to be notochordal vestiges remained from embryogenesis. It is currently unknown whether EPs can, in rare instances, develop into chordoma.
- ▶ **Design:** Genomic DNA was extracted from formalin-fixed paraffin-embedded specimen of BNCTs and EPs and analyzed using aCGH for copy number changes.
- ▶ **Results:** Preliminary aCGH data showed that a benign notochordal cell tumor and an echordosis physaliphora lack the complex genomic alteration seen in the majority of conventional chordomas, and instead contain more focal copy number changes at several loci. Furthermore, the aCGH data showed no loss of p16 or PTEN, and no amplification of brachyury, changes commonly detected in chordomas.
- ▶ **Conclusions:** Our aCGH results suggest that the deletion of p16 and PTEN loci, the amplification of brachyury gene, and the complex genomic alterations are relatively late events in the pathogenesis of chordoma, and opens the possibility that other unexplored alterations may be important in the early tumorigenesis of chordoma.

Category: Bone & Soft Tissue

