

Con el aval científico de:



Sociedad Española de Anatomía Patológica

Madrid, 9 de mayo de 2012

USCAP & AACR HIGHLIGHTS

Neuropatología

Dra. Marta Couce – Hosp. Univ. Son Espases, Mallorca
Dr. Aurelio Ariza – Hosp. Univ. Germans Trias i Pujol, Barcelona
Dra. M^a Dolores Bautista – Hosp. Reg. Univ. Carlos Haya, Málaga

USCAP
& AACR
HIGHLIGHTS
2012

[1779] SOX2 Immunoexpression in High-Grade Gliomas: Potential Marker for Targeted Therapy

Gitika Aggarwal, Suash Sharma. Medical College of Georgia, Georgia Health Sciences University, Augusta, GA

- ▶ **Background:** Gliomas may arise from neuroectodermal stem or progenitor cells. SOX (SRY-like HMG box) genes may be of particular interest as these represent a family of transcriptional cofactors implicated in the control of embryonic development of CNS. It is highly expressed within the embryonic neuroectodermal progenitors, and is downregulated as neural cells exit the cell cycle and differentiate. SOX genes are amplified/ upregulated in tumors, and Sox2 is overexpressed in malignant glioma. Sox2 silencing in glioblastoma tumor-initiating cells inhibits proliferation in mice. We aimed to study the distribution of Sox-2 positive cells in high-grade (malignant) gliomas.
- ▶ **Design:** A total of 44 malignant gliomas (WHO grades 3 and 4) were identified from pathology archives. These were diagnosed and graded using WHO classification. These included 39 glioblastomas (GBM), 2 gliosarcomas (GS), 2 anaplastic astrocytomas (AA) and 1 anaplastic oligodendroglioma (AO). Sox2 immunohistochemistry was performed on formalin-fixed paraffin embedded tissue from these cases. The staining was reviewed for percentage positivity of tumor cells, staining intensity semiquantitatively (1+ to 4+), and various tumor patterns including positivity in infiltrating tumor cells (ITC), pseudopalisading, perivascular and pleomorphic tumor giant cells (PGC).
- ▶ **Results:** All 44 (100%) malignant gliomas exhibited nuclear positivity of neoplastic cells. The control non-neoplastic autopsy brain tissues did not show any staining of normal cells or those in reactive gliosis. Of the tumors that showed specific patterns, 41/41 showed Sox2 positivity in ITC, 37/42 in perivascular tumor cell aggregates, 25/29 in pseudopalisading cells, and 5 had positivity in subpial accentuation. PGC were identified to be positive in 11/11 cases, including 1 GS. The sarcomatous component of GS was negative. Of note, endothelial cells in microvascular proliferation were negative. Only 11/44 (25%) showed <100% tumor cell staining varying from 5% to 90%, including 2 GS and 3 grade-3 gliomas.
- ▶ **Conclusions:** The present study confirmed the strong immunoexpression of Sox2 in high grade gliomas, including all GBMs, and was undetectable in normal cortex. Since SOX2 immunoexpression in this study was also noted in infiltrating as well as perivascular and pseudopalisading (hypoxic) tumor cells, which are relatively refractory to chemoradiation, anti-Sox-2 targeted immunotherapy carries the potential to complement conventional therapy in high-grade gliomas.

Category: Neuropathology

[1780] Molecular Genetic and Clinical Characteristics of Glioblastoma with Oligodendroglial Component (GBM-O)

Christina L Appin, Candace S Chisolm, Cristina Vincentelli, Charlie Hao, Stephen B Hunter, Daniel J Brat. Emory University School of Medicine, Atlanta, GA

- ▶ **Background:** Glioblastoma with oligodendroglial component, WHO grade IV (GBM-O) is a recently recognized subtype of GBM (WHO, 2007) with little known of its distinguishing clinical or molecular features. Common genetic alterations in classic GBM include EGFR amplification (amp, 40-50%), *PTEN* deletion (del, 80-90%), and MGMT promoter methylation (40-50%). Chromosome 1p and 19q co-deletion (co-del) is frequent in oligodendrogliomas (60-80%), but occurs in less than 5% of GBMs. Mutant IDH1 is present in 5-10% of primary GBMs and 70-80% of secondary GBMs. Here we describe molecular genetic and clinical features of GBM-O.
- ▶ **Design:** Results of molecular testing on GBMs diagnosed from 2008 to 2011 at Emory University were analyzed. DNA methylation of the MGMT promoter was determined by methylation-specific PCR. *EGFR*, *PTEN*, 1p and 19q status were determined by fluorescence in situ hybridization (FISH). Immunohistochemistry was used to determine mutant IDH1 expression (IDH1R132H). Age at diagnosis and gender were also noted.
- ▶ **Results:** Between 2008 and 2011, a total of 252 GBMs were diagnosed and 31 (12%) were classified as GBM-O. Patients with GBM-O were younger than those with classic GBMs (mean, 50.6 yrs vs. 58.6 yrs, respectively; Student's t test $p = 0.04$) and the majority were men (80% of GBM-O vs. 57% of classic GBM). MGMT promoter methylation status was not substantially different between GBM-O and GBM (45% vs 50%, respectively). EGFR was amplified in 38% of classic GBMs compared to 26% of GBM-O. Almost all (95%) classic GBMs showed *PTEN* del compared to 75% of GBM-O. Co-del of 1p/19q was noted in 31% of GBM-O. Mutant IDH1 protein was detected in 31% of GBM-Os and 9% of classic GBMs.
- ▶ **Conclusions:** GBM-O affects younger patients and a higher percentage of males than classic GBM. The spectrum of genetic alterations in GBM-O is slightly different than classic GBMs, with lower frequencies of EGFR amp and *PTEN* del and higher frequencies of 1p/19q co-del and *IDH1* mutation.

Category: Neuropathology

[1787] The Troubling Differential Diagnosis of Extracerebellar Pilocytic Astrocytoma with Atypical Features and High-Grade Pediatric Glioma: Clinical, Histopathologic and Molecular Analyses of 16 Cases

Matthew Cykowski, Richard Allen, Kar-Ming Fung, Ethan Stolzenberg, Terence Dunn. University of Oklahoma Health Sciences Center, Oklahoma City, OK

- ▶ **Background:** Pilocytic astrocytoma (PA) is the most common glioma of childhood, recognized in classic form by a constellation of radiologic and pathologic findings. Rarely, PAs acquire a spectrum of atypical features (e.g., marked atypia, necrosis, infiltrative growth, elevated mitotic rate) that raises the differential diagnoses of atypical/anaplastic PA versus pediatric glioblastoma multiforme (pGBM). This study examines the histologic, immunohistochemical, and molecular features that might aid in this distinction, particularly considering the recently reported high rate of *BRAF* missense mutations in extracerebellar PAs.
 - ▶ **Design:** 10 PAs (9 atypical, 1 anaplastic, 8 extracerebellar, 4 recurrent) and 6 pGBMs were retrieved from institutional archives (1999-2011). Quantitative morphologic parameters (observer-independent Ki-67 and p53 labeling indices (LI), mitotic rate/20 hpfs) were compared using the Kolmogorov-Smirnov test. Qualitative morphologic parameters (presence of marked atypia, endothelial proliferation, atypical mitoses, and extent and pattern of necrosis) were compared using the Chi-square test. Pyrosequencing of *BRAF* (codon 600), *IDH1* (codon 132), and *IDH2* (codon 172) and dideoxynucleotide sequencing of *TP53* (exons 5-9) was performed following PCR of DNA isolated from representative tissue sections.
 - ▶ **Results:** Significant differences were seen between PAs and pGBMs in mitotic rate (PA = 4.3, pGBM = 21.2), atypical mitoses, (2/10 PAs, 6/6 pGBM), pseudopalisading necrosis (5/6 pGBMs), and Ki-67 LI (PA = 18.9 %, pGBM = 34.5 %). No other morphologic features met significance criteria, including extent of necrosis and p53 nuclear LI (only 2 pGBMs and 1 anaplastic PA had p53 LIs \geq 50 % with the latter case demonstrating a TP53 c.841G>A mutation). No *IDH1* or *IDH2* mutations were detected. *BRAF* V600E mutation was seen in 1 extracerebellar PA; upon closer examination of deeper sections this tumor was found to harbor rare, non-entrapped ganglion cells.
 - ▶ **Conclusions:** PAs with atypical/anaplastic features and pGBMs differed in select microscopic parameters, including atypical mitoses and Ki67 LIs (5/6 pGBMs having LIs \geq 26 %). Although reported in anaplastic PA, pseudopalisading necrosis was specific to pGBM in this series. There was considerable overlap in other histologic and molecular parameters. This case series also indicates that careful histologic review and further phenotypic study of *BRAF* V600E-mutated PAs is warranted.
- Category: Neuropathology

[1791] The Diagnostic Utility of Brain Biopsy in Patients with Clinical Suspicion of Encephalitis and Non-Enhancing CNS Lesions

Gillian L Genrich, Jeff Gelfand, Ari Green, Bruce Cree, Tarik Tihan. University of California at San Francisco, San Francisco

- ▶ **Background:** The clinical manifestations of encephalitis are highly diverse and the differential diagnosis includes numerous infectious and noninfectious processes. Brain biopsy is an invasive diagnostic modality of last resort, in patients for whom CSF analyses and neuroimaging do not yield conclusive diagnoses. The diagnostic utility of biopsies in such cases is not well established. In patients who do undergo biopsy, the diagnosis may be interpreted as encephalitis without specific features. The clinical outcomes in this particular patient cohort are useful in determining the value of an invasive procedure in definitive diagnosis.
 - ▶ **Design:** We reviewed Department of Pathology archives for all cases submitted with a clinical suspicion of encephalitis from 1989-2010. The search algorithm identified all cases in which "encephalitis" appeared in the clinical differential diagnosis and in the final pathology report. For cases, the clinical symptoms at presentation, histopathologic features and diagnoses on brain biopsy, and follow-up information were gathered from electronic medical records and physician files.
 - ▶ **Results:** We identified 130 patients (87 males, 43 females; mean age 41 years) with a clinical suspicion and pathological diagnosis of encephalitis. The diagnoses were encephalitis, not otherwise specified (NOS) in 79 cases, specific viral encephalitis in 28 cases, toxoplasma encephalitis in 11 cases, paraneoplastic (limbic) encephalitis in 3 cases, fungal encephalitis in 2 cases, and Rasmussen's encephalitis in 2 cases. Other diagnoses included *Balamuthia sp.*, *Pseudallescheria boydii*, larva migrans, tuberculosis and granulomatous encephalitis NOS (1 case each). In the "encephalitis, NOS" group, there were 47 males and 32 females (mean age, 41 years). The "NOS" diagnosis was changed to a specific diagnosis after retrospective histopathologic review in 5 cases. Clinical follow-up revealed a specific diagnosis in 23 cases. The diagnoses could not be further specified in 51 cases.
 - ▶ **Conclusions:** The initial diagnostic yield of brain biopsies in patients with a suspicion of "encephalitis" and with diffuse radiological abnormalities without enhancement was 39%. Among the biopsies with "encephalitis NOS," a specific etiology was not determined in 51 cases after follow-up. The overall nonspecific diagnoses (39%) even after follow-up necessitates a more cautious approach to brain biopsy in encephalitis cases, and the use of an algorithm to maximize the diagnostic yield.
- Category: Neuropathology

[1794] Pleomorphic Xanthoastrocytoma: A Single Institution Experience

Cristiane M Ida, Kiernan J Minehan, Sarah M Jenkins, Nadia N Laack, Bernd W Scheithauer, Caterina Giannini. Mayo Clinic, Rochester, MN; Mayo Clinic, La Crosse, MN

- ▶ **Background:** Pleomorphic xanthoastrocytoma (PXA), a rare astrocytic tumor with relatively favorable prognosis, corresponds to WHO grade II. It is currently uncertain if PXA with histological features of anaplasia, so-called "PXA with anaplastic features" (PXA-AF), should be considered anaplastic (WHO grade III).
- ▶ **Design:** We studied 49 patients operated at (39) or referred to (10) our Institution, with histologically confirmed PXA (1950-2011). Clinical and therapeutic data and follow-up were obtained from medical records. Slides available for review in 66 tumors from 46 patients (13 with ≥ 2 resections) were reassessed for features of anaplasia, including mitotic index (MI) $\geq 5/10$ HPF, necrosis (N) and endothelial proliferation (EP). Recurrence-free and overall survival were estimated with Kaplan-Meier methods and compared between PXA and PXA-AF with log rank tests.
- ▶ **Results:** Patients included 28M and 21F, median age at diagnosis 21.5 yrs (8-57). Tumors were supratentorial in 47 cases (43% involving temporal lobe). Seizures were the presenting symptoms in 64% of patients. Extent of tumor removal was total in 24, subtotal in 20, biopsy-only in 1 and unknown in 4 cases. Features of anaplasia (PXA-AF) were present in 16 cases (13 at first resection; 3 at recurrence), and included MI $\geq 5/10$ HPF (7), N (2), MI $\geq 5/10$ HPF + N (4), MI $\geq 5/10$ HPF + EP (1) or MI $\geq 5/10$ HPF + N + EP (2). Median follow-up was 5 yrs (0.1-29.1) and 3.4 yrs (0.1-19.3) for PXA and PXA-AF, respectively. Recurrence occurred in 19 patients: 14 PXA (39%), 4 of which also progressed to PXA-AF, and 5 PXA-AF (38%). Three (of 36) patients with PXA died of disease, and all had progressed from PXA to PXA-AF (at 0.3, 3 and 3.6 yrs from progression). Three (of 13) patients with PXA-AF died of disease (at 0.9, 1.1 and 4.7 yrs from first resection). After first resection, 10 PXA patients and 6 PXA-AF patients received radiotherapy, chemotherapy or a combination. Additional treatment generally followed recurrence. Recurrence-free 5-year survival rates were 75% and 50% ($p=0.34$) and overall 5-year survival rates were 95% and 82% ($p=0.05$) for PXA and PXA-AF patients, respectively.
- ▶ **Conclusions:** This study confirms that overall survival is significantly decreased in PXA-AF when compared to classic PXA, raising the consideration that PXA-AF may correspond to a higher grade tumor.

Category: Neuropathology

[1797] Pilocytic Astrocytomas with Infiltrating Patterns of Growth Carry a High Rate of BRAF V600E Mutation

Gokul Kandala, Sergui Bannykh, Sean Fan, Kevin Baden, Andy Pau, Lara Baden, Patricia Fournier, Erica Thorpe, Kathy Porpora, James Mirocha, Kevin Kawachi, Amin Riley-Portuges, Jean Lopategui. Cedars-Sinai Medical Center, Los Angeles, CA

- ▶ **Background:** Pilocytic Astrocytoma (PA), a WHO grade 1 tumor, shows two frequent alterations in BRAF oncogene. The V600E point mutation, which is the most common tumor-associated alteration in the BRAF gene and an alternative BRAF activating mechanism that involves BRAF-KIAA1549 gene fusion with corresponding duplication at chromosome band 7q34. Although the majority of PAs are well circumscribed, a subset shows an invasive pattern akin to biologically different infiltrative gliomas. We investigated whether the presence of a BRAF point mutation and/or duplication in PAs correlate with an infiltrating pattern of growth.
- ▶ **Design:** We identified 19 cases of PAs with brain infiltration (5 from NF1 patients) and matched them with 18 localized PAs for a total of 37 cases. Infiltration was assessed by histology and MRI. 26 cases were in adults and 11 in children. V600E mutation was identified by an allelic discrimination PCR mutational kit. Coriel Repository HBT-38 cell line was used as a positive control. FISH studies utilized Abbott Molecular kit with probes for both CEP7 (Green) and 7q34 BRAF containing region (Gold). In each case, 50 cells were evaluated. In the cells with two green signals, presence of two gold signals indicated wild type whereas three a duplication. Cases with over 20% of cells with a gain of BRAF were scored positive for duplication. Both tests were done on all cases. Statistical analysis was performed using two group Fisher's-exact test of equal proportions. This compared infiltrative vs non-infiltrative tumors with V600E mutation.
- ▶ **Results:** BRAF abnormality by either PCR or FISH was seen in 17/37 cases. The V600E mutation and the gene duplication were mutually exclusive except for one case. 6 cases showed a V600E mutation. Strikingly, 5/6 cases with the point mutation showed distinct brain infiltration. 5/14 infiltrating PAs (excluding patients with NF1) had the V600E mutation, whereas only 1/18 non-infiltrating tumors had this pathogenic point mutation. This difference attained a p-value of 0.064 by using Fisher's-exact test of equal proportions. Duplication of the BRAF gene was seen in 12/37 cases. In contrast to V600E mutation, the duplication was non-discriminatory in respect to infiltration of the PAs. Of 5 tumors in NF1 patients, one was positive for duplication and none for point mutation.
- ▶ **Conclusions:**
 1. Presence of BRAF V600E mutation appears to correlate with an infiltrating pattern of PAs in non-NF1 patients.
 2. Duplication of the BRAF gene in PA is present in both infiltrative and localized tumors.
 3. BRAF abnormalities are rare in NF1 PAs.

Category: Neuropathology

[1805] Morphologic Correlates of the Alternative Lengthening of Telomeres (ALT) Phenotype in High Grade Astrocytomas

Doreen N Nguyen, Christopher M Heaphy, Roeland F de Wilde, Brent Orr, Charles G Eberhart, Alan K Meeker, Fausto J Rodriguez. Johns Hopkins Medical Institutions, Baltimore, MD

- ▶ **Background:** Recent studies have highlighted the occurrence of a telomerase-independent mechanism of telomere maintenance known as "alternative lengthening of telomeres" (ALT) in subsets of human cancers. An increased frequency of ALT has been described in infiltrating gliomas in particular, and associated with *ATRX* mutations. We retrospectively reviewed high grade astrocytomas to uncover correlations between ALT, *ATRX* expression, histology and molecular alterations typical of infiltrating astrocytomas.
- ▶ **Design:** We studied 117 high grade astrocytomas with available ALT status (19 WHO grade III and 98 WHO grade IV tumors). Histologic review was performed, as well as immunohistochemistry for *ATRX*, *DAXX*, and mutant *IDH1* protein. *EGFR* amplification was evaluated by Fluorescence in situ hybridization (FISH). Molecular and immunohistochemical studies were performed using tissue microarrays, while histologic evaluation was performed in whole H&E sections in a subset of cases with available slides (n=37). Oligodendroglial neoplasms were excluded from analysis.
- ▶ **Results:** ALT was identified in 40 cases (34%), including 17 (89%) grade III astrocytomas, and 23 (24%) grade IV astrocytomas. When focusing on histologic subtypes, all small cell astrocytomas (n=6) and the single giant cell astrocytoma were ALT negative. The ALT phenotype was also correlated with the presence of round cells, fine chromatin, and microcysts, although these features were almost always present in grade III tumors. The ALT phenotype was positively correlated with the presence of *IDH1* mutant protein ($p<0.0001$), *ATRX* protein loss ($p<0.0001$), and absence of *EGFR* amplification ($p=0.004$). There was no significant correlation with *DAXX* expression.
- ▶ **Conclusions:** ALT represents a specific phenotype with distinctive pathologic and molecular features. Further studies are needed to clarify the clinical and biological significance of ALT in high grade astrocytomas.

Category: Neuropathology

[1807] Efficacy of Transplant Media for Muscle Biopsy Sample Preservation

Kunle O Ojemakinde, Jon D Wilson. Louisiana State University Health Sciences Center, Shreveport, LA

- ▶ **Background:** One of the limitations in the pathologic evaluation of muscle biopsy is the time interval between the biopsy procedure and the snap freezing of the sample. Timely freezing of the sample in liquid nitrogen cooled isobutane not only gives excellent frozen section morphology, but also preserves tissue biochemistry and nucleic acids. The latter allow for accurate enzyme histochemical staining and/or subsequent biochemical and genetic testing. Institutions that refer muscle samples to a specialist are often too far to transport these time-sensitive specimens by courier and/or do not have the capability to snap freeze the muscle biopsy on premises.
Transport media are used to preserve organ donor explants during shipment. A prior report indicates that use of transport medium preserved the enzyme histochemistry of pig muscle biopsy samples for up to five days. We assessed the preservation quality of two transport media on human muscle.
- ▶ **Design:** Skeletal muscle tissue was sampled from freshly amputated leg specimens. The samples were divided into five portions in each of the two transport mediums ("Belzer UW Cold Storage Solution" and "Lifor ACF perfusion media"), and Carnoy's fixative. One portion was snap frozen in liquid nitrogen cooled isobutane immediately. The remaining four were placed in a sterile conical tube containing 50ml of transport medium or Carnoy's fixative, and refrigerated at 4 degrees centigrade. One portion of muscle per each successive day (days 2 through 5) was snap frozen from each transport medium or preservative. Frozen sections from each of the five samples were cut and stained at the same time. Staining included hematoxylin and eosin, modified Gomori Trichrome, PAS and PASd, and enzyme histochemistry. The enzyme histochemical stains included ATPase at pHs 9.4 and 4.3, NADH-TR, alkaline phosphatase, acid phosphatase, cytochrome oxidase, succinic acid dehydrogenase, and myophosphorylase.
- ▶ **Results:** Both transport media preserved enzymatic activities and provided good frozen section morphology for up to 5 days. Compared to the standard frozen biopsy specimens, biopsies processed from transport media contained some artifacts, such as cell shrinkage and/or tissue edema. Lifor ACF perfusion media showed somewhat more tissue edema than Belzer UW Cold Storage Solution. The sample preserved in Carnoy's fixative did not perform well.
- ▶ **Conclusions:** Our results confirm that organ transplant media represent a viable solution for preserving muscle biopsies for morphologic and enzyme histochemical assessment.

Category: Neuropathology

[1815] BRAF V600E Mutation Is Seen in 50% of Adult Pleomorphic Xanthoastrocytoma with Anaplastic Features but Does Not Predict Prognosis for Individual Patients

Yao X Schmidt, BK Kleinschmidt-DeMasters, Dara L Aisner, Kevin O Lillehei, Denise Damek. University of Colorado Denver SOM, Aurora, CO

- ▶ **Background:** Pleomorphic xanthoastrocytoma with anaplastic features (PXA-A) is an uncommon tumor about which little is known regarding prognostic factors. Indeed, debate exists as to which histological features (number of mitoses, MIB-1 rate, necroses) best correlate with anaplasia in this tumor type. PXAs often have *BRAF V600E* mutation, although the actual percentage of + cases is variable. Dias-Santagata et al. found 60% of PXAs WHO grade II and 17% of PXA-As + for mutation, whereas Schindler et al. identified mutation in 63-69% of PXAs WHO grade II and 38% of adult PXA-As and 100% of pediatric PXA-As. It is unknown if the mutation has value for predicting individual patient outcome. In addition, virtually no information exists about immunohistochemistry for IDH-1 in PXA-A.
- ▶ **Design:** Eleven cases of adult PXA-A were reviewed. Ten cases were assessed for the *BRAF V600E* mutation by PCR and ten for IDH-1 by IHC.
- ▶ **Results:** Patients ranged in age from 18-68 years; 5/11 PXA-As affected temporal lobe and 2/11 tumors were cystic. 5/11 had gross total resection; all but 2 received external beam cranial irradiation; 10/11 received adjuvant chemotherapy (TMZ, BCNU). A dichotomy existed for survival: 4 survived less than 2 years. Long term survivors, in contrast, are alive at 7, 9.3, 10.9, and 11.4 years post diagnosis. Of these long term survivors, only 2 of 4 manifested *BRAF V600E* mutation. Interestingly, these two patients were amongst the youngest ages in the cohort, at 18 and 28 years. Another young patient (22 years) did possess the *BRAF V600E* mutation, but succumbed to his disease 1.7 years after diagnosis; he received only subtotal resection and was the single patient who refused post-operative chemo- or radiotherapy, underscoring the need for adjuvant treatment. Correlating with the series by Schindler et al. that suggest higher incidence of *BRAF* mutation in pediatric versus adult PXA-As, in our series, 3 of 4 patients over age 45 years were negative; a 68-year-old did show *BRAF* mutation; her survival after diagnosis was 1.9 years. Almost all patients were negative for IDH-1 immunoreactivity.
- ▶ **Conclusions:** *V600E BRAF* mutation is seen in at least 50% of PXA-As in adults; mutational status has no positive or negative predictive value for individual patients in terms of survival. Positive mutation is not exclusive to younger-aged individuals. Negative IDH-1 by IHC is usually identified in PXA-As of adults.

Category: Neuropathology

[1818] Cavernous Angiomas in Chronic Epilepsy Associated with Focal Cortical Dysplasia

Elizabeth R Severson, Derrick J Chen, Richard A Prayson. Cleveland Clinic, Cleveland, OH

- ▶ **Background:** Both cavernous angiomas and focal cortical dysplasia (FCD) are well recognized causes of medically intractable epilepsy. In a subset of patients with chronic epilepsy, multiple pathologies may coexist (eg: focal cortical dysplasia adjacent to ganglioglioma or dysembryoplastic neuroepithelial tumor). Anecdotal causes of FCD adjacent to cavernous angiomas have been documented in the literature. This study systematically reviews a series of cavernous angiomas in epileptic patients, looking for evidence of coexistent FCD.
- ▶ **Design:** One hundred forty six patients were diagnosed with cavernous angiomas on resection specimens from January, 1989, to May, 2011. Histologic slides were reviewed from these cases in order to confirm the diagnosis and to identify cases which had ample tissue adjacent to the lesion to evaluate for FCD. Eighteen cases who also had epilepsy qualified for study. FCD was classified according to criteria outlined by Palmini et al (Neurology 2004;62(Suppl 3)S2-8).
- ▶ **Results:** Patients included 10 females (55.6%) and 8 males (44.4%) with a mean age of 38.5 years (median 39 years; range 21 to 51 years) at the time of resection. All patients had a history of epilepsy (median 11 years) prior to surgery. Seventeen cavernomas were located in the temporal lobe and one in the occipital lobe; 9 were located on the left side and 9 on the right side. Adjacent FCD was identified in 13 out of the 18 cases (72.2%). The FCD in these cases were classified as type Ia (N=8; 61.5%), type Ib (N=4; 30.8%), and type IIa (N=1; 7.7%). After resection, a majority of the patients experienced resolution of epilepsy (N=14; 77.8%). Of the four patients that did not experience resolution, 2 had evidence of adjacent FCD (type Ia = 1, type Ib = 1) and 2 did not.
- ▶ **Conclusions:** Focal cortical dysplasia is frequently present in association with cavernous angiomas in patients with chronic epilepsy. The type of FCD seen adjacent to these lesions vary, but most are Palmini et al type I. With resection of the cavernous angiomas and adjacent FCD, resolution of epilepsy may be achieved.

Category: Neuropathology

[1825] Quantitative Analysis of MGMT Promoter Methylation in Glioblastoma Multiforme

Bin Yang, Rosemarie Read, Raymond Tubbs. Cleveland Clinic, Cleveland, OH

- ▶ **Background:** *O*⁶-Methylguanine-DNA methyltransferase (MGMT) is a DNA repair enzyme that specifically removes alkyl groups from the *O*⁶ position of guanine in DNA. Repair of *O*⁶-alkylguanine adducts by tumour cells has been implicated in drug resistance since it reduces the cytotoxicity of alkylating chemotherapeutic agents. Recent clinical trial reveals that glioblastoma patients with MGMT methylation had much better response to temozolomide and median survival nearly doubled than those without MGMT methylation. In order to provide this molecular biomarker in guidance of chemosensitivity, we have developed and validated MGMT methylation assay using pyrosequencing on small biopsy specimens of glioblastoma multiforme.
- ▶ **Design:** Promoter methylation of MGMT was quantitatively analyzed in 43 cases of glioblastoma multiforme and 10 cases of non-neoplastic epilepsy brain tissue. MGMT methylation profile is analyzed quantitatively using Pyro Q96 on paraffin-embedded biopsy tissues. The analytical sensitivity and minimal requirement of DNA volume and biopsy size is evaluated. Two cell lines, one harboring of MGMT methylation and another free of MGMT methylation were included as positive and negative controls. The sensitivity between pyrosequencing and methylation-specific PCR was also compared.
- ▶ **Results:** Using a cutoff at 10%, methylation of MGMT was identified in 33% (11/33) cases of glioblastoma and 0% of the non-neoplastic epilepsy brain tissue. The range of percentage of methylation of any CpG island in MGMT promoter is 33-95% with a mean of 65%. By a series dilution of a methylated cancer cell line with an unmethylated normal cell line, pyrosequencing can detect 5% of tumor cells harboring MGMT methylation. The minimal amount of genomic DNA required to be able to successfully detect MGMT methylation by pyrosequencing is at 100 ng (approximately 3,000 cells). In comparison with MSP, pyrosequencing is comparably sensitive with less false-positive cases and also provide quantitative methylation value of each CpG island.
- ▶ **Conclusions:** We have studied and validated the quantitative MGMT methylation assay on small biopsy tissue from patients with glioblastoma. We demonstrate that pyrosequencing detection of MGMT methylation has an analytical sensitivity suitable for clinical utility. MGMT methylation assay can provide a useful molecular biomarker for prediction of chemosensitivity in patients with glioblastoma multiforme.

Category: Neuropathology

[1814] Impact of Oncogenic Alterations on MGMT Promoter Methylation Status in Glioblastoma (GBM)

Yuan Rong, Cristina Vincentelli, Candace Chisolm, Jeffrey J Olson, Charlie Hao, Stephen B Hunter, Daniel J Brat. Emory University School of Medicine, Atlanta, GA

- ▶ **Background:** GBM is the most common primary malignant brain tumor and consists of multiple genetic subtypes. *O*⁶-methylguanine – DNA methyltransferase (*MGMT*) is a key DNA repair enzyme that antagonizes chemotherapy-induced DNA crosslinking at the *O*⁶ position of guanine. *MGMT* promoter methylation, found in ~ 40% GBMs, is associated with reduced *MGMT* expression, enhanced response to temozolomide and improved survival. Here we investigate correlations between specific genetic alterations and *MGMT* promoter methylation in GBM.
- ▶ **Design:** Results of molecular testing on 120 primary GBMs diagnosed from 2008 to 2010 at Emory University were analyzed. Methylation of the *MGMT* promoter was determined by methylation-specific PCR. *EGFR* amplification (amp) and *PTEN* deletion (del) were detected by fluorescence in situ hybridization (FISH). Immunohistochemistry was used to detect mutant *IDH1* expression (*IDH1*R132H).
- ▶ **Results:** Among GBMs in this study, *MGMT* promoter methylation was detected in 55 of 120 (46%); *EGFR* amp in 45 of 120 (38%); *PTEN* del in 72 of 78 (92%); both *EGFR* amp and *PTEN* del in 27 of 73 (37%); and *IDH1* mutation in 13 of 109 (12%). *MGMT* promoter methylation was present in 25 of 45 (56%) cases with *EGFR* amp and in 25 of 75 (33%) with wt *EGFR* (Fisher's exact test, $p < 0.05$); 34 of 72 cases (47%) with *PTEN* loss and in 3 of 6 (50%) with *PTEN* intact; and in 19 of 27 (70%) with both *EGFR* amplification and *PTEN* loss ($p < 0.05$). *MGMT* promoter methylation was present in 9 of 13 (69%) cases with mutant *IDH1* protein detected and in 44 of 96 (46%) without mutant *IDH1* detected ($p = 0.1$).
- ▶ **Conclusions:** Our results indicate that *MGMT* promoter methylation is most frequent in those GBMs with *EGFR* amplification and *IDH1* mutation.

Category: Neuropathology

Case 2 - Cerebral Phaeohyphomycosis, Due to Bipolaris Spicifera

Rebecca D. Folkerth - Brigham & Women's Hosp, Boston, MA

► Introduction:

55yo M with hypertrophic cardiomyopathy, status post orthotopic heart transplant 6 weeks prior

- On mycophenolate mofetil, prednisone, and cyclosporine

At routine post-op visit, complained of 2 days of frontal headache and lethargy

- Headache constant, 8/10, bifrontal, and unaffected by position; alleviated slightly by acetaminophen
- No fever, neck stiffness, or vomiting
- Wife reported he was less "like himself", with paucity and slowing of speech, and emotional blunting

No recent travel or sick contacts; cats at home

Employed as a high school woodshop teacher, on leave for several weeks surrounding his heart transplant

On examination

- T 96.7°F
- BP 160/70 mmHg
- Alert, oriented, and appropriately interactive, though with a reduced range of affect
- Occasional paraphasic errors, and difficulty relaying complex portions of his history
- Mild flattening of right nasolabial fold
- Strength decreased in right triceps (4+/5) and bilateral ankle dorsiflexion (4/5)
- Slight right pronator drift and decreased rapid finger-tapping with the right hand

Labs: WBC count 7.36; cyclosporine trough level was 243 ng/mL (therapeutic range: 100-400 ng/mL).

Magnetic resonance imaging:

- Axial T1 with gadolinium

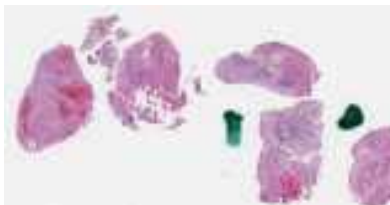3cm lesion with nodular signal heterogeneity

- Axial FLAIR

Increased relative cerebral blood volume, moderate vasogenic edema, and 7mm midline shift

► Pathological/Microscopic Findings and any Immunohistochemical or Other Studies:

Brain biopsy is diagnostic, showing mixed chronic inflammatory reaction, often granulomatous and/or centered around cerebral blood vessels. Pigmented hyphae are readily seen, and can be confirmed with fungal stains (PAS, methenamine silver).



Slide 1

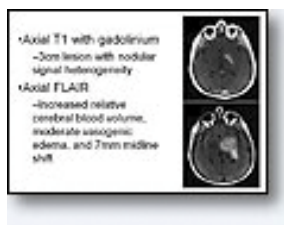


Figure 1
Neuroimaging

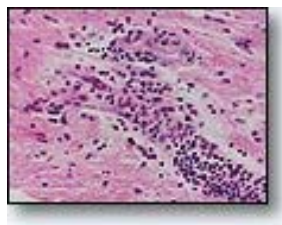


Figure 2
H&E 400x

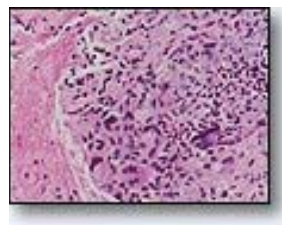


Figure 3
H&E 400x

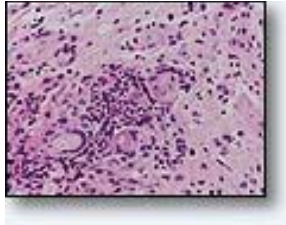


Figure 4
H&E 400x

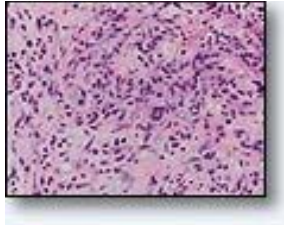


Figure 5
H&E 400x

► **Differential Diagnoses:**

Based on the clinical presentation and neuroimaging findings, the differential is:

- Abscess (Toxo, Fungus)
- Tumor (Lymphoproliferative disorder, Glioma)
- Vascular lesion ??

► **Final Diagnosis:**

Cerebral Phaeohyphomycosis, Due to *Bipolaris Spicifera*

► **Case Discussion:**

Phaeohyphomycosis refers to infection by a pigmented (“dematiaceous”) fungus. These organisms have melanin in their cell walls, and may appear grossly pigmented (black) when infecting the skin. Upon microbiologic culture, the colonies also are darkly pigmented. The agent is normally found in soil or decayed wood, and most frequently affects farmers. (In this case, the patient was a woodworker.) The usual route of infection is inhalation, explaining the high incidence of involvement of lungs or paranasal sinuses. (In this case, a route of infection was not identified, but was presumably via inhalation.) It is highly neurotropic, and can involve any part of the brain. It usually forms an abscess with mass effect, and may secondarily involve the meninges, including the dura mater.

Importantly, unlike many other fungal infections of the brain, phaeohyphomycosis affects both immunocompetent and immunocompromised hosts (i.e., is not considered opportunistic).

On neuroimaging, it appears as a “ring-enhancing” lesion with a core of low-attenuation signal, which can mimic high-grade glioma or metastasis. Because of this radiographic differential, biopsy is usually desired clinically, for definitive diagnosis.

Laboratory testing may reveal elevated serum galactomannin levels, however, biopsy with culture is the only means to establish the identity of the infectious agent, and to prescribe appropriate azole antifungal therapy.

► **Review of the Literature/Treatment Options (if applicable):**

Over 106 orders of fungi have been implicated, and new species are continually being identified. (The agent cultured in this case, *Bipolaris spicifera*, is relatively uncommon, mentioned in only 4 case reports in the literature. By contrast, *Xylohypha* (*Cladophialophora*) *bantiana* (mentioned in the case report by Dr. Scheithauer, published in 1993) is highly represented, seen in 48% of cases. This infection requires treatment with azole antifungals, despite which a high rate of mortality is associated.

► **Conclusion(s):**

Cerebral phaeohyphomycosis is a distinctive cerebral infection, occurring in the immunocompetent as well as immunocompromised host, with typical pigmented hyphae in a granulomatous response.

► **References:**

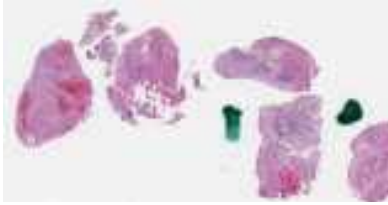1. Hauck EF, McGinnis M, Nauta HJ. Cerebral phaeohyphomycosis mimics high-grade astrocytoma. *Journal of Clinical Neuroscience* 2008 Sep; 15(9):1061-6.
2. Palaoglu S, Sav A, Basak T, Yalcinlar Y, Scheithauer BW. Cerebral phaeohyphomycosis. *Neurosurgery*. 1993 Nov;33(5):894-7.
3. Revankar SG, Sutton DA, Rinaldi MG. Primary central nervous system phaeohyphomycosis: A review of 101 cases. *Clinical Infectious Diseases* 2004; 38:206-16.
4. Rosow L, Jiang JX, Deuel T, Lechpammer M, Zamani AA, Milner DA, Folkerth R, Marty FM, Kesari S. Cerebral phaeohyphomycosis caused by *Bipolaris spicifera* after heart transplantation. *Transpl Infect Dis*. 2011 Aug;13(4):419-23.

Case 3 - Germinoma of the Basal Ganglia

Gregory N. Fuller, MD Anderson Cancer Center, Houston, TX

Clinical History

A 20-year-old man presented with a two-day history of intermittently slurred speech. There was no history of other signs or symptoms, including no history of headache, nausea, vomiting, motor or sensory deficits, visual disturbance, seizures or altered level of consciousness. A non-contrast CT scan performed in the Emergency Department revealed a 4-cm-diameter heterogeneous mass in the region of the left basal ganglia (putamen and globus pallidus). Subsequent MR imaging demonstrated that the basal ganglia mass displayed heterogeneous contrast enhancement, central hypointense areas of apparent necrosis, and surrounding vasogenic edema. Stereotactic biopsy was performed.



Slide 1

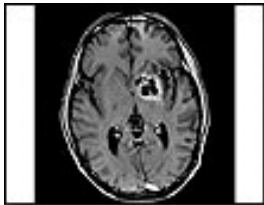


Figure 1

MRI. Axial T1-weighted image (T1WI) with contrast. A multicystic enhancing mass located in the left basal ganglia region is seen.

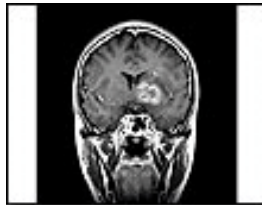


Figure 2

MRI. Coronal T1WI with contrast. A multicystic enhancing mass located in the left basal ganglia region is seen.

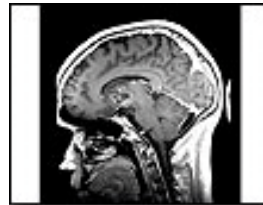


Figure 3

MRI. Sagittal T1WI with contrast. A multicystic enhancing mass located in the left basal ganglia region is seen.

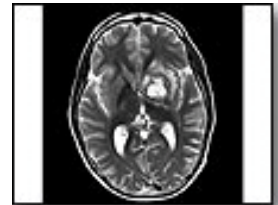


Figure 4

MRI. Axial T2-weighted image (T2WI). Very little surrounding edema (hyperintensity on T2-weighted sequences) is seen.

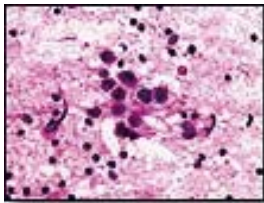


Figure 5

H&E. Intraoperative consultation cytologic smear preparation shows a biphasic population, with large atypical germinoma cells interspersed with small reactive lymphocytes.

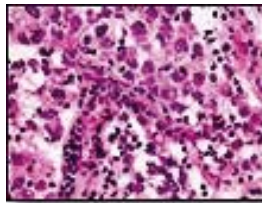


Figure 6

H&E. Intraoperative consultation frozen section confirms the representative nature of the smear prep, with clusters of large atypical germinoma cells interspersed with small reactive lymphocytes.

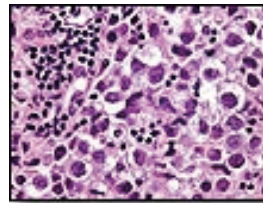


Figure 7

H&E. FFPE permanent tissue sections also exhibit characteristic architectural and cytologic features of germinoma.

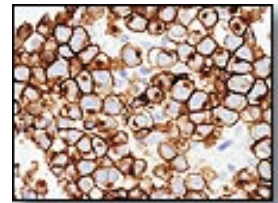


Figure 8

CD117 (c-KIT). Germinoma shows strong reactivity for CD117 in a prominent membranous staining pattern with associated cytoplasmic positivity.

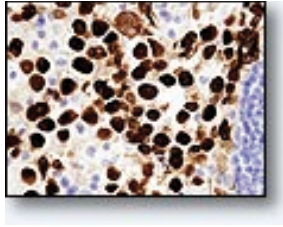


Figure 9

SALL4. The transcription factor SALL4 is strongly expressed in germinoma nuclei.

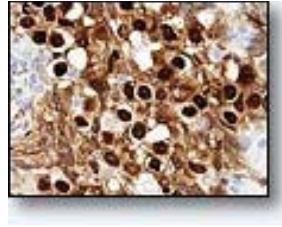


Figure 10

OCT4. The currently preferred marker for confirming a diagnosis of germinoma is the transcription factor OCT4, which is a very robust marker showing strong nuclear positivity.

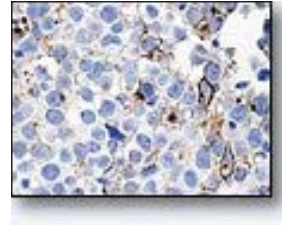


Figure 11

Placental alkaline phosphatase (PLAP). Once the mainstay of germinoma immunodiagnosis, PLAP is a relatively weak marker (compare this representative field with similar fields in figures 8, 9 and 10 showing OCT4, c-KIT, and SALL4 reactivity) that has fallen into disuse.

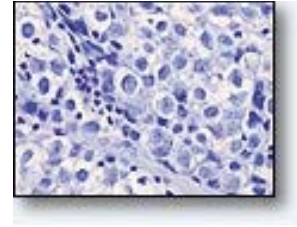


Figure 12

Beta-hCG. Germinomas are negative for CD30 (which is strongly and diffusely positive in embryonal carcinoma), alpha-fetoprotein (which is strongly and diffusely positive in yolk sac tumor) and beta-hCG (which is strongly and diffusely positive in choriocarcinoma), with the exception that many germinomas contain b-hCG-positive syncytiotrophoblastic cells (these were not seen in the present case).

► **Pathological/Microscopic Findings and any Immunohistochemical or Other Studies:**

The characteristic biphasic cell population, with large atypical germinoma cells interspersed with small reactive lymphocytes on intraoperative consultation cytologic smear preparations often provides the first strong indication of a diagnosis of germinoma. Confirmation of the diagnosis is provided by demonstration of strong nuclear immunoreactivity for the robust transcription factor OCT4. Other strongly positive markers include SALL4 (nuclear) and CD117 (c-KIT; membranous and cytoplasmic). Placental alkaline phosphatase (PLAP) immunostaining formerly enjoyed widespread use to confirm a diagnosis of germinoma, but this marker is notoriously capricious and, because reactivity is frequently only patchy and/or pale, has fallen into desuetude with the arrival of far more robust markers such as OCT4, CD117 and SALL4.

► **Differential Diagnoses:**

- Germinoma
- Embryonal carcinoma
- Choriocarcinoma
- Glioblastoma
- Metastatic carcinoma

► **Final Diagnosis:**

Germinoma of the Basal Ganglia

► **Case Discussion:**

Germinoma is the most common germ cell tumor (GCT) of the central nervous system, followed by mixed germ cell tumor, and then teratoma (with mature more common than immature). “Pure” embryonal carcinoma, choriocarcinoma or yolk sac tumor do occur but are very rare, and when present usually comprise a component of mixed germ cell tumor.

The most common location within the CNS in which germinoma arises is the pineal gland, followed by the suprasellar region. The basal ganglia /thalamic region is third in frequency, with up to 15% of germinomas arising in this location. Basal ganglia germinoma (BGG) can be difficult to diagnose for three main reasons. First, because this location is a relatively rare site of origin, germinoma is often not thought of when formulating the differential diagnosis. Secondly, the symptoms of germinoma of the basal ganglia are often ill-defined and evolve slowly, usually with gradual onset of hemiparesis. And thirdly, the initial imaging features of BGG frequently range from extremely subtle to virtually undetectable unless there is a degree of suspicion on the part of the radiologist or surgical pathologist. Moreover, rather presenting as a mass lesion, the initial imaging abnormality of many early BGGs is exactly the opposite: hemiatrophy of the involved basal ganglia and ipsilateral cortex. Only later in the course of the disease does a contrast-enhancing mass (as seen in the present case) evolve. Recent imaging data suggest that susceptibility-weighted imaging (SWI) sequences may be the most sensitive in detecting early, non-enhancing BGG. Even when BGG presents as an obvious enhancing mass, because of its rarity, the clinical team may not think of it as an entity to be included in the differential diagnosis unless one has been previously encountered. In the present case, BGG was not a part of the initially formulated neuroimaging differential, which included such things as glioblastoma and atypical lymphoma, and it was the surgical pathologist who suggested BGG as the most

likely cause of the mass at the time of intraoperative consultation. Young patient age in the 10-20 year old range, especially in male patients, coupled with a unilateral or bilateral lesion of the basal ganglia region is a strong clue to include BGG in the preoperative differential diagnosis.

The gender incidence of CNS germinoma shows a definite overall male predilection, but this is an oversimplification because suprasellar germinomas actually exhibit a slight, but definite, female predilection. The common pineal germinoma shows a strong male predilection, but the male predominance in BGG is even more pronounced, with cases arising in females being the subject of case reports.

Most BGGs arise unilaterally, but bilateral BGG, occurring either synchronously or metachronously, are well-recognized, and in fact represent the second most common multiple germinoma scenario after paired pineal and suprasellar germinoma.

Other germ cell tumors (GCTs) may very rarely arise in the basal ganglia region, including mixed germ cell tumors. In such instances, as in germ cell tumors arising at any body site, application of a panel of immunomarkers generally provides a definitive diagnosis. The Table shows some of the most helpful markers in current use. The SALL4 transcription factor is a generally excellent pan-germ cell tumor maker that strongly labels the nuclei of germinoma, embryonal carcinoma and yolk sac tumor, albeit with weaker nuclear staining seen in choriocarcinoma. SALL4 has also been claimed in recent studies to be a more robust marker for yolk sac tumor than alpha-fetoprotein or glypican3. OCT4, another transcription factor (and hence showing nuclear localization) is a very robust marker for germinoma and embryonal carcinoma. These two germ cell tumors can usually be distinguished based on H&E features when adequate well-preserved tissue is available; however, in the real world of shrinking biopsy size and increasing surgical artifact optimal tissue is not always available, and the application of immunomarkers greatly facilitates diagnosis – in this case use of CD117 (c- KIT) and CD30 will resolve the differential, with CD117 strongly labeling germinoma, and CD30 strongly labeling embryonal carcinoma. Yolk sac tumor (or a yolk sac tumor component of a mixed germ cell tumor) can be distinguished immunophenotypically from germinoma and embryonal carcinoma by demonstrating expression of alpha-fetoprotein. And finally, choriocarcinoma exhibits strong diffuse expression of beta-hCG to an extent that is not seen in the other three tumors. Of note, placental alkaline phosphatase (PLAP), formerly used to confirm germinoma, has been supplanted by the much more robust marker OCT4.

▶ **Practical Germ Cell Tumor Markers**

	SALL4	OCT4	CD117	CD30	a-FP	b-hCG
Germinoma	++++	++++	++++	-	-	+/- syncyt
Embryonal ca	++++	++++	-	++++	-	+/- syncyt
Yolk Sac Tumor	++++	-	-	-	+++	+/- syncyt
Choriocarcinoma	++	-	-	-	-	++++

Regarding beta-hCG expression, although diffuse positivity in a majority of tumor cells is characteristic only of choriocarcinoma, scattered syncytiotrophoblasts can be seen in all types of GCTs, including germinoma, and these cells exhibit strong reactivity for beta-hCG. The significance of the presence of a beta-hCG-positive component of syncytiotrophoblasts in otherwise “pure” germinoma has been extensively studied and debated, and in fact continues to be studied and debated. Many germinomas are accompanied by elevated serum beta-hCG, and the question of what level correlates with the presence of a choriocarcinoma component of a mixed GCT, and with a less favorable prognosis than “pure” germinoma, remains debated and under study. Regarding biopsy interpretation, the current conventional wisdom favors including germinoma with scattered syncytiotrophoblastic cells under the rubric of “pure” germinoma, rather than classifying them as mixed GCTs; however, their presence should be noted in the pathology report. Some clinical studies stratify GCT patients into three tiers, with the most favorable group including “pure” germinoma and mature teratoma; an intermediate tier that includes germinoma with elevated beta-hCG, multifocal/disseminated germinoma, immature teratoma, and mixed germinoma with mature teratoma; and a poor prognosis tier composed of “pure” embryonal carcinoma, choriocarcinoma or yolk sac tumor and mixed GCTs in which any of these three tumors is a major component.

▶ **Conclusion(s):**

1. The basal ganglia/thalamic region is the 3rd most common site for germinoma of the CNS.
2. Early lesions may be very subtle and difficult to visualize on MR imaging studies, and imaging at initial clinical presentation may show hemiatrophy of the basal ganglia region and the ipsilateral cerebral cortex, rather than a mass lesion
3. Even when presenting as a contrast-enhancing mass, basal ganglia germinoma requires knowledge of the entity to raise the index of suspicion and include it in the differential diagnosis
4. In the context of a unilateral or bilateral lesion(s) localized to the basal ganglia, young patient age (in the vicinity of 10-20 years old) and male gender should trigger inclusion of basal ganglia germinoma high on the differential diagnosis.

► **References:**

1. Wang XL, Li CJ. [The early diagnosis of juvenile germinoma originating from the basal ganglia and thalamus]. *Zhonghua Nei Ke Za Zhi*. 2011 Apr;50(4):307-10. Chinese. PubMed PMID: 21600150.
2. Rasalkar DD, Chu WC, Cheng FW, Paunipagar BK, Shing MK, Li CK. Atypical location of germinoma in basal ganglia in adolescents: radiological features and treatment outcomes. *Br J Radiol*. 2010 Mar;83(987):261-7. Epub 2009 Sep 14. Review. PubMed PMID: 19752170.
3. Lou X, Ma L, Wang FL, Tang ZP, Huang H, Cai YQ, Wong EH. Susceptibility-weighted imaging in the diagnosis of early basal ganglia germinoma. *AJNR Am J Neuroradiol*. 2009 Oct;30(9):1694-9. Epub 2009 Jul 6. PubMed PMID: 19581340.
4. Hao S, Liu B, Tang J, Jia G, Zhang Y, Ma Z, Wang Z. Germinoma of basal ganglia in female: case report and review of the literature. *Childs Nerv Syst*. 2009 May;25(5):613-7. PMID: 19082612.
5. Lee J, Lee BL, Yoo KH, Sung KW, Koo HH, Lee SJ, Choi JY, Lee KH, Lee JI, Shin HJ, Kim JH, Suh YL, Lee KH, Lee M. Atypical basal ganglia germinoma presenting as cerebral hemiatrophy: diagnosis and follow-up with 11C- methionine positron emission tomography. *Childs Nerv Syst*. 2009 Jan;25(1):29-37. PMID: 18712399.
6. Sakai K, Shigeta H. Serial MR and CT features of primary germinoma originating in the basal ganglia. *J Clin Neurosci*. 1999 Mar;6(2):162-164. PMID:18639143.
7. Fujii Y, Saito Y, Ogawa T, Fujii S, Kamitani H, Kondo S, Horie Y, Togawa M, Senda M, Maegaki Y, Ohno K. Basal ganglia germinoma: diagnostic value of MR spectroscopy and (11)C-methionine positron emission tomography. *J Neurol Sci*. 2008 Jul 15;270(1-2):189-93. PMID: 18371980.
8. Villani A, Bouffet E, Blaser S, Millar BA, Hawkins C, Bartels U. Inherent diagnostic and treatment challenges in germinoma of the basal ganglia: a case report and review of the literature. *J Neurooncol*. 2008 Jul;88(3):309-14. PMID: 18365143.
9. Wong TT, Chen YW, Guo WY, Chang KP, Ho DM, Yen SH. Germinoma involving the basal ganglia in children. *Childs Nerv Syst*. 2008 Jan;24(1):71-8. Epub 2007 Sep 29. PubMed PMID: 17906866.
10. Rossi A, Garrè ML, Ravegnani M, Nozza P, Abbruzzese A, Giangaspero F, Tortori-Donati P. Bilateral germinoma of the basal ganglia. *Pediatr Blood Cancer*. 2008 Jan;50(1):177-9. PubMed PMID: 16700048.
11. Okamoto K, Ito J, Ishikawa K, Morii K, Yamada M, Takahashi N, Tokiguchi S, Furusawa T, Sakai K. Atrophy of the basal ganglia as the initial diagnostic sign of germinoma in the basal ganglia. *Neuroradiology*. 2002 May;44(5):389-94. PMID: 12012122.
12. Elizabeth J, Menon G, Bhattacharya RN, Radhakrishnan VV. Germinoma of the basal ganglia: a case report and review of literature. *Neurol India*. 2002 Mar;50(1):84-6. PubMed PMID: 11965648.
13. Sugimoto K, Nakahara I, Nishikawa M. Bilateral metachronous germinoma of the basal ganglia occurring long after total removal of a mature pineal teratoma: case report. *Neurosurgery*. 2002 Mar;50(3):613-6; discussion 616-7. PubMed PMID: 11841731.
14. Liu E, Robertson RL, du Plessis A, Pomeroy SL. Basal ganglia germinoma with progressive cerebral hemiatrophy. *Pediatr Neurol*. 1999 Apr;20(4):312-4. PMID: 10328283.
15. Wong LW, Jayakumar CR. Germinoma of the basal ganglia and thalamus-- CT and MRI findings. *Singapore Med J*. 1997 Oct;38(10):444-6. PMID: 9529959.
16. Kobayashi T, Kageyama N, Kida Y, Yoshida J, Shibuya N, Okamura K. Unilateral germinomas involving the basal ganglia and thalamus. *J Neurosurg*. 1981 Jul;55(1):55-62. PMID: 7241216.
17. Yamada H, Imamura K, Sakai N, Ando T, Hirata T, Misao H, Sakata K, Shimokawa K. [Intracerebral germinoma developing in the right basal ganglia- -report of a case followed up by CTscan and review of the literature (author's transl)]. *No To Shinkei*. 1980 Apr;32(4):387-92. Japanese. PMID: 7378202.
18. Villani A, Bouffet E, Blaser S, Millar BA, Hawkins C, Bartels U. Inherent diagnostic and treatment challenges in germinoma of the basal ganglia: a case report and review of the literature. *J Neurooncol*. 88:309-14, 2008. PMID: 18365143.
19. Wong TT, Chen YW, Guo WY, Chang KP, Ho DM, Yen SH. Germinoma involving the basal ganglia in children. *Childs Nerv Syst* 24:71-78, 2008. PMID: 17906866.
20. Rossi A, Garrè ML, Ravegnani M, Nozza P, Abbruzzese A, Giangaspero F, Tortori-Donati P. Bilateral germinoma of the basal ganglia. *Pediatr Blood Cancer* 50:177-179, 2008. PMID: 16700048.
21. Cao D Li J, Guo CC, Allan RW, Humphrey PA. SALL4 is a novel diagnostic marker for testicular germ cell tumors. *Am J Surg Path* 33:1065-1077, 2009.
22. Mei K, et al. Diagnostic utility of SALL4 in primary germ cell tumors of the central nervous system: a study of 77 cases. *Modern Pathol* 22:1628-1636, 2009.
23. Hattab EM. Germ cell tumors. Chapter 15 in: Perry A, Brat D, eds. *Practical Surgical Neuropathology*. Philadelphia: Elsevier, 2010.

Case 5 - Abeta Related Angiitis (Primary CNS Angiitis Associated with Amyloid Angiopathy) Causing a Mass Like Lesion

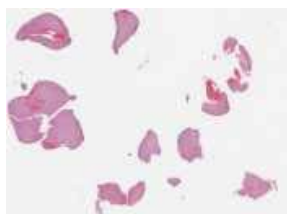Caterina Giannini, Mayo Clinic, Rochester, MN

Clinical History

The patient is a 74-year-old man, who began noting intermittent difficulty with expressive language. He had problems coming up with the name of a familiar neighbor as well as remembering the name of an ingredient for stew. There was no associated weakness, alteration in awareness, vision, or sensation. A brain CT and subsequently an MRI were obtained. The CT showed an area of low attenuation in the left temporal lobe with tiny associated area of hyperattenuation. A subsequent MRI showed a left temporal large mildly enhancing lesion with mass effect as well as several other areas of abnormal T2 signal in both hemispheres. He underwent a stereotactic biopsy of the left temporal lobe lesion with the clinical suspicion of low- to intermediate-grade glioma, likely multifocal.



Slide 1



Slide 2

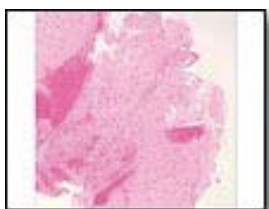

Figure 1

MRI. Axial T1-weighted image (T1WI) with contrast. A multicystic enhancing mass located in the left basal ganglia region is seen.

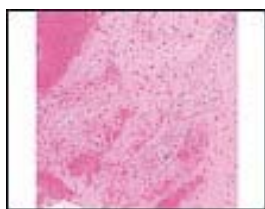


Figure 2

MRI. Coronal T1WI with contrast. A multicystic enhancing mass located in the left basal ganglia region is seen.

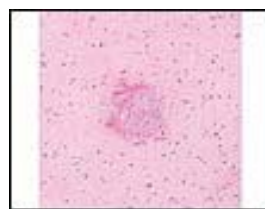


Figure 3

MRI. Sagittal T1WI with contrast. A multicystic enhancing mass located in the left basal ganglia region is seen.

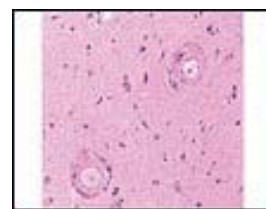


Figure 4

MRI. Axial T2-weighted image (T2WI). Very little surrounding edema (hyperintensity on T2-weighted sequences) is seen.

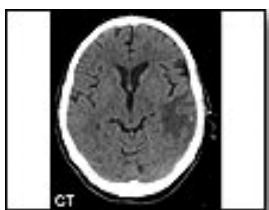

Figure 5

Preoperative-CT

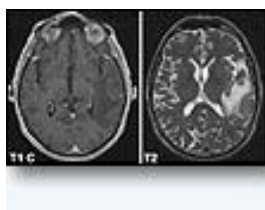


Figure 6

Preoperative-MRI

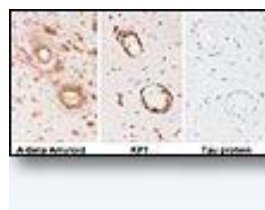


Figure 7

A-beta amyloid immunostain shows marked A-beta deposits in the vascular walls as well as a moderate number of amyloid plaques surrounding the vessels. Macrophages are present in the vascular walls. Tau protein is negative. There is no evidence of neuritic plaques or neurofibrillary tangles.

► **Introduction:**

Elderly patients presenting with central nervous system mass lesions are biopsied with the concerns of malignancy.

► **Pathological/Microscopic Findings and any Immunohistochemical or Other Studies:**

Two H&E slides are submitted for examination, each containing multiple small gray and superficial white matter tissue fragments admixed with a moderate amount of fresh blood. The tissue appears to be relatively normal with normal cellularity. There is some diffuse non specific gliosis, but no evidence of atypia to suggest a primary infiltrative glial neoplasm, as clinically suggested. Several small cortical vessels have thickened walls with an eosinophilic homogeneous appearance. Some in addition show presence of a cellular infiltrate composed mostly of pale histiocytes. On slide A, a small tissue fragment shows two adjacent vessels, one cut longitudinally with prominent histiocytes and scattered giant cells. The vascular lumens are nearly occluded and fibrin seems to permeate the vascular wall. Immunohistochemical studies reveal intense A- beta amyloid positivity in the vascular wall of most cortical small vessels, in which presence of histiocytes is confirmed by the macrophage stain KP1. A-beta amyloid deposits are present in the cortex as diffuse plaques. A tau protein stain for neurofibrillary tangles is completely negative.

► **Differential Diagnoses:**

- Incidental finding of age related cerebral amyloid angiopathy (CAA) in an otherwise non diagnostic biopsy – Advise rebiopsy
- Cerebral amyloid angiopathy (CAA) causing a mass like lesion
- Abeta related angiitis (ABRA) / primary CNS angiitis associated with amyloid angiopathy causing a mass like lesion
- Amyloidoma

► **Final Diagnosis:**

Abeta Related Angiitis (Primary CNS Angiitis Associated with Amyloid Angiopathy) Causing a Mass Like Lesion

► **Case Discussion:**

Non-neoplastic lesions are not infrequently encountered in patients presenting with an intracerebral mass and undergoing biopsies with a clinical diagnosis of tumor, typically high grade. Cerebral amyloid angiopathy (CAA) is a relatively common and important disorder occurring predominantly in older patients. It is characterized by the extracellular deposition in the blood vessel walls of highly insoluble amyloid fibrils with beta-pleated secondary structures (Ferrer et al). The most common form of CAA is sporadic and associated with deposition of A- beta, a cleavage product of amyloid-beta precursor protein (APP), normally expressed in endothelial cells, pericytes and smooth muscle cells of CNS blood vessels. Prevalence of sporadic CAA increases with age over age 60 and is high among patients with Alzheimer's disease to which is highly interrelated. Inherited CAA is rare and associated with seven different amyloidogenic proteins, including APP.

Sporadic A-beta CAA is responsible for up to 12% of primary non traumatic parenchymal hemorrhages. Based on our institutional experience, intracerebral hemorrhage represents the most common manifestation of amyloid angiopathy diagnosed in a surgical biopsy accounting for approximately 50% of patients. Typically patients present with large life threatening parenchymal "lobar" hemorrhages, which are evacuated surgically while surrounding parenchyma is biopsied. The remaining patients instead present with a mass and/or mental status changes and are frequently thought to have a tumor. It is important to entertain this diagnostic possibility in the differential diagnosis, since ordering key immunohistochemical tests allows for a specific diagnosis in this setting. Angiocentric inflammatory infiltrates have been described in a subset of A-beta CAA and associated with a distinct clinical syndrome, which may respond to immunosuppressive treatment (Eng et al). Primary angiitis of the CNS (PACNS), predominantly granulomatous, also occurs in association with CAA. In our series of PACNS, beta-A4 amyloid deposition was present in approximately 50% of the granulomatous vasculitis group, which was the most common pattern of vasculitis observed in surgical biopsies (Miller et al, Salvarani et al). Scolding et al reported a group of these patients with stereotyped clinical, radiological and pathological features under the name of A-beta-related angiitis (ABRA). The patients are older (60-70 years) than other PACNS patients, often present with altered mental status, headaches or seizures and focal neurological deficits associated frequently with white matter hyperintensities on MRI and seems to show a favorable response to immunosuppression. It is unclear if/how A-beta amyloid deposits induce inflammation and/or vasculitis or if A-beta deposits represent just bystander products of vasculitis causing chronic increase in vascular permeability, leakage of first soluble A-beta and ultimately deposition of A-beta amyloid in the wall of damaged vessels. The occurrence of ABRA at an earlier age as compared to CAA favors the first hypothesis.

Localized accumulation of AL lambda light chain-derived amyloid resulting in mass like amyloidomas can also occur in the central nervous system and usually involves white matter and choroid plexus (Laeng et al). Amyloid deposits occur within white matter interstitium and perivascularly and typically result from AL lambda deposition. In these cases, amyloid can be characterized by histochemical stains (e.g. Congo red) and more specific immunohistochemistry for kappa and lambda immunoglobulin light chains. The recent introduction of mass spectrometry-based proteomics provides an additional powerful tool with exquisite sensitivity and specificity that may help in evaluating the composition of amyloid deposits in cases that are equivocal by immunohistochemistry (Rodriguez et al). Most cases of primary CNS amyloidoma are secondary to localized monoclonal plasma cell proliferations and are often associated with a scant perivascular infiltrate of light chain restricted plasma cells in most cases.

► **Conclusion(s):**

Cerebral amyloid angiopathy (CAA) and primary angiitis of the CNS associated with cerebral amyloid angiopathy (ABRA) are relatively common and important disorders occurring predominantly in older patients. It is important for the pathologist to entertain this diagnostic possibility when examining biopsies from elderly patients presenting with CNS mass lesions. While findings may be subtle and could be easily overlooked, appropriate immunohistochemical tests may easily allow for a specific diagnosis in this setting. The recognition that at least a subset of these patients significantly benefit from immunosuppressive treatment makes CAA and ABRA important pathological diagnoses.

► **References:**

1. Briceno CE, Resch L, Bernstein M Cerebral amyloid angiopathy presenting as a mass lesion, *Stroke* 1987;18:234-9
2. Eng JA, Frosch MP, Choi K, Rebeck GW, Greenberg SM Clinical manifestations of cerebral amyloid angiopathy-related inflammation *Ann Neurol* 2004;55:250-6
3. Ferrer I, Kaste M, Kalimo H Vascular diseases in Greenfield's Neuropathology 8th Ed (Editors Love S, Louis DN, Ellison DW), London 2008;1: 142-6
4. Rodriguez FJ, Gamez JD, Vrana JA, Theis JD, Giannini C, Scheithauer BW, Parisi JE, Lucchinetti CF, Pendlebury WW, Bergen HR 3rd, Dogan A. Immunoglobulin derived depositions in the nervous system: novel mass spectrometry application for protein characterization in formalin-fixed tissues. *Lab Invest* 2008;88:1024-37
5. Laeng RH, Altermatt HJ, Scheithauer BW, Zimmermann DR. Amyloidomas of the nervous system: a monoclonal B-cell disorder with monotypic amyloid light chain lambda amyloid production. *Cancer* 1998;82:362-374.
6. Miller DV, Salvarani C, Parisi JE, et al. Primary central nervous system vasculitis: a clinicopathologic study of 51 patients. *Am J Surg Pathol*. 2009;33:35-43.
7. Salvarani C, Brown Jr RD, Calamia KT, Christianson TJ, Weigand SD, Miller DV, et al. Primary central nervous system vasculitis: analysis of 101 patients. *Ann Neurol* 2007; 62(5):442-51.
8. Scolding NJ, Joseph F, Kirby PA, Mazanti I, Gray F, Mikol J, Ellison D, Hilton DA, Williams TL, MacKenzie JM, Xuereb JH, Love S. Abeta-related angiitis: primary angiitis of the central nervous system associated with cerebral amyloid angiopathy. *Brain*. 2005;128:500-15.

